

## The Possible Pre-emptive Role of Royal Jelly and Alpha Lipoic Acid on Osteoporosis Caused by Glucocorticoid in Adult Male Albino Rats

Mai Hassan Ibrahim\*, Marim Fayz Abdow

Anatomy & Embryology Department, Faculty of Medicine, Benha University, Benha, Egypt

\*Corresponding Author: Mai Hassan Ibrahim, Mobile: (+20)01145779734,

Email: may.ibrahim@fmed.bu.edu.eg, ORCID: 0000-0001-5999-2612

### ABSTRACT

**Introduction:** extreme or extended glucocorticoid (GC) management may lead to high risk of bone fractures and osteoporosis (OP). Alpha lipoic acid and Royal Jelly are effective anti-oxidants. **Objective:** This study examined effects of glucocorticoid on the bone structure and the possible preventive role of alpha Lipoic acid and royal jelly.

**Materials and Methods:** Forty rats were categorized into four groups. Control group, glucocorticoid group: rats were administrated with glucocorticoid at a dose of 30 mg/kg/day S.C for 60 days, third group rats were given Glucocorticoid and 100 mg/kg/day of alpha lipoic acid orally for 60 days. Group IV: rats were given glucocorticoid and royal jelly 100 mg/Kg /day orally for 2 months. Bone specimens were prepared for the histological and immunohistochemical studies.

**Results:** Glucocorticoid induced resorption and damage of the bone histological structure. Percent of both collagen fiber deposition and osteopontin immunoreactivity were markedly decreased in comparison with the control group. Royal jelly and alpha lipoic acid reversed the damage effect of glucocorticoid on the bone histological structure.

**Conclusion:** Chronic use of glucocorticoid in adult male albino rats caused osteoporosis that could be reversed by administration of royal jelly and alpha lipoic acid.

**Keywords:** Glucocorticoid, Alpha lipoic acid, Royal jelly, Osteoporosis.

### INTRODUCTION

The bone is an unfamiliar tissue in that, many types of hormones are required to control its growth, remodeling and maturation. It is being regularly manufactured, damaged, and recreated in a process called bone reforming<sup>(1)</sup>. There are two levels regulate this dynamic process. Systemic hormones, as parathyroid hormones, sex steroid hormones, calcitonin, growth hormone, and cortisol, at the first level<sup>(2)</sup>. The balance between the activities of bone-forming osteoblasts and bone-resorbing osteoclasts, is the other regulation level<sup>(3)</sup>.

Osteoporosis is a silent illness, defined as a systemic skeletal disease manifested by decreased bone mass and micro tissue construction damage of bone tissue, with a resultant increase in bone fragility, compromised bone strength and an increased risk of fractures that are not due to substantial trauma<sup>(4)</sup>.

Glucocorticoids (GCs) are extensively used to treat various diseases as immunosuppressive diseases. But, extreme or prolonged treatment with it, increase the liability of bone fractures and osteoporosis (OP). Glucocorticoid-induced osteoporosis (GIOP) developed in about 35-50% of patients treated with prolonged GC<sup>(5)</sup>.

GIOP is a secondary osteoporosis, it is different from the primary osteoporosis, which includes senile, postmenopausal and juvenile osteoporosis<sup>(6)</sup>.

Royal jelly (RJ) has been utilized globally as marketable medicinal products, cosmetics and health foods. It is composed chemically of lipids, sugars, vitamins, and proteins<sup>(7)</sup>. It implicates many active biological substances as antibacterial protein and 10-hydroxy-2-decenoic acid<sup>(8)</sup>. RJ can be useful for osteoporosis, as it includes testosterone and has actions like other steroid hormones. Although RJ has been conventionally known to advance post-menopausal

manifestation, few who studied its role in inhibiting the loss of bone tissue, which is the most harmful symptoms of post-menopausal women<sup>(7)</sup>.

Destruction of collagen and other bone-related proteins in the osteoporosis process may mediated by highly reactive hydroxyl radical (OH)<sup>(9)</sup> which in turn produced by reaction between O<sub>2</sub> and H<sub>2</sub>O<sub>2</sub> with tartrate-resistant acid-phosphatase. This chemical compound presented highly in osteoclast of the bone tissue<sup>(10)</sup>.

Alpha-lipoic acid (ALA) is an anti-oxidative agent that can be made both by animals and plants. It can scavenge ROS, like the superoxide anion (O<sub>2</sub>) and hydrogen peroxide (H<sub>2</sub>O<sub>2</sub>), decreasing loss of bone during osteoporosis<sup>(11)</sup>.

### MATERIALS AND METHODS

#### Experimental animals:

Forty adult male albino rats aged 16-20 weeks and weighing 185-225 grams were used in this study. The animals were housed in plastic cages with a metallic mesh cover and dimension of 50×40×30 cm<sup>3</sup>. Each cage contained five animals. The animals were fed an ordinary laboratory diet, vegetables and bread with a liberal supply of water. The used rats were divided into four groups (each was formed of 10 rats): control group, osteoporosis (glucocorticoid treated) group, glucocorticoid + ALA treated group, glucocorticoid + royal jelly treated group.

#### Ethical Consent:

All the experimental procedures were carried out according to the principles and guidelines of the Ethics committee of the Faculty of veterinary medicine at Benha University, Benha- Egypt conformed to the Guide for the care and use of Laboratory Animals, Published by US National

Institutes of Health (NIH Publication No. 39/12.062022).

#### Drugs:

**Methylprednisolone:** Depo- Medrol ampoule 80mg/2ml, obtained from Pfizer company, Egypt.

**Alpha- lipoic acid(ALA):** Thiotacid 600mg (Thioctic Acid = Alpha Lipoic Acid ) tablet was purchased from Eva Pharma, Egypt. The tablet dissolved in 6 ml distilled water at a concentration of 100 mg/ml.

**Royal jelly:** 1000mg capsules were obtained from Pharco Pharmaceuticals, Alexandria, Egypt. ; it is prepared for supplementation by dissolving it in 10ml distilled water at a concentration of 100 mg/ml.

#### Experimental design:

**Group 1 (Control group):** included ten rats, and was divided into 3 subgroups;

**Subgroup 1a:** Three rats were put in the experimental situation like the exposed group but were injected with saline subcutaneously for 2 months and was served as a sham-exposed group.

**Subgroup 1b:** Four rats were given distilled water orally by gastric tube and was served as sham-exposed group.

**Subgroup 1c:** Three rats were received only a standard diet and tap water, the animals of the 3 subgroups were sacrificed after 2 months from the start of the experiment.

**Group 2 (glucocorticoid treated group):** Animals were injected by methyl-prednisolone in a dose of 30mg/kg/day subcutaneously for 2 months. This dose is correspondent to a human dosage of 7.5 mg, generally recommended for rheumatic disease <sup>(12)</sup>.

**Group 3 (glucocorticoid + ALA treated group):** Rats were injected with methyl-prednisolone in the same dose as the previous group for 2 months, the rats were administrated simultaneously with ALA solution with a gastric tube in a dose of 100mg/kg/day for the same period <sup>(11)</sup>.

**Group 4 (glucocorticoid + Royal jelly treated group):** Rats were injected with methyl-prednisolone in the same dose as group II, and were fed by gastric tube with RJ in a dosage of 100mg/kg B.W per day simultaneously <sup>(13)</sup>.

One day after the last dose, rats of all studied groups were anesthetized with intraperitoneal injection of sodium thiopental 200mg/kg BW <sup>(14)</sup> Then, the shaft of the femur of all animals was cautiously dissected and handled for histological studies.

#### Histopathological study:

The upper part of shaft of each femur was fixed in 10% formalin for 5 days. It was washed with tap water and decalcification carried out in the chelating agent disodium EDTA. Decalcification continued for around 28 days, during which the solution was changed every 2 days till tissues had softened. The time for exposure to the decalcification will vary; closely monitoring the progress is needed <sup>(15)</sup>. The decalcified shaft of the

femur was longitudinally cut along the central portion in a coronal plane and specimens were handled to form paraffin blocks. Serial transverse sections of 5 µm thickness were done and subjected to the following:

#### A- Histological stains:

1- Haematoxylin and Eosin stain <sup>(16)</sup>: was used to exhibit the histological structure of rat's shaft of the femur between different experimental groups. Nuclei were stained dark blue, the cytoplasm was stained varying degrees of pink.

2- Masson's trichrome stain <sup>(17)</sup> : For demonstration of collagen fibers. Collagen fibers were stained blue, cytoplasm and nuclei were stained red.

3- Alizarin stain:

Adherent cells were detached with 0.25% trypsin containing 50mM EDTA and cultured in Petri dishes. The culture medium was substituted with fresh -MEM medium supplemented with FCS (10%), dexamethasone ( $10^{-8}$  M),  $\beta$ -glycerophosphate (10 µM) and freshly prepared AA (50 µg/ ml) after 24 hours. Alizarin Red staining was used to identify calcified tissue in culture <sup>(18)</sup>.

#### B-Immunohistochemical study:

Osteopontin immunostaining  
Specimens were brood (incubated) with anti-osteopontin (OPN) rabbit polyclonal antibody which has cross-reactivity with rats, utilizing the avidin biotin peroxidase method to evaluate the localization of osteopontin in bone. OPN immunoreactivity with strong staining is clear in cement line, osteoblast, osteocytes and bone matrix. Negative control sections were processed by substituting the primary antibody with buffer alone. <sup>(19)</sup>.

All these sections were examined and photographed using Olympus light microscope (Tokyo, Japan) coupled to an Olympus digital camera (DXC-1850P, Tokyo, Japan) in Anatomy & Embryology Department, Faculty of Medicine, Benha University.

#### C- Morphometric study and statistical analysis:

Serial Sections of Masson Trichrome stained sections and OPN immunostained sections were morphometrically analyzed for measuring the mean area % of collagen fiber deposition and the area % of Osteopontin immunoreactivity in all groups respectively . This was performed in 5 non overlying fields of 5 different sections from 5 different rats in each group at  $\times 200$  by using the image analysis program " Leica Qwin 500 " software image analyzer.

Data were conveyed as mean  $\pm$  SD.  $p \leq 0.05$  was regarded as being statistically significant ; this is established by using One way ANOVA and post hoc multiple comparisons by using SPSS software (v.19; Chicago, USA).

## RESULTS

#### Histological Observations:

Tissue analysis of control subgroups; Ia, Ib and Ic revealed nearly the same configuration. We used figures

of the control subgroup Ic to differentiate with other groups. Histological inspection of H&E stained slices of compact bone of femur diaphysis of control subgroup Ic revealed normal histological structure. It revealed outer cortex, Osteocytes were seen inside their lacunae. Bone formation appeared as basophilic cement line separating between the newly formed matrix and the older bone. Endosteum of the cortex lined by osteoblasts (Figure .1a ).

Cancellous bone of the same group was formed of thick, continuous bone trabeculae enclosing bone marrow spaces of variable sizes. (Figure. 2a ).

Femur diaphysis sections of compact bone of glucocorticoid treated group (group II) showed less acidophilia of matrix. The osteocytes appeared with pyknotic nuclei. Moreover, multinucleated osteoclasts were also seen in areas of bone resorption (Figure 1b).

The cancellous bone of this group revealed apparent thin trabeculae with wide bone marrow cavities. Multiple areas of weakly stained matrix were seen in bone trabeculae (Figure 2b).

**Group III (Glucocorticoid + alpha lipoic acid treated group)** histology of group III appeared nearly

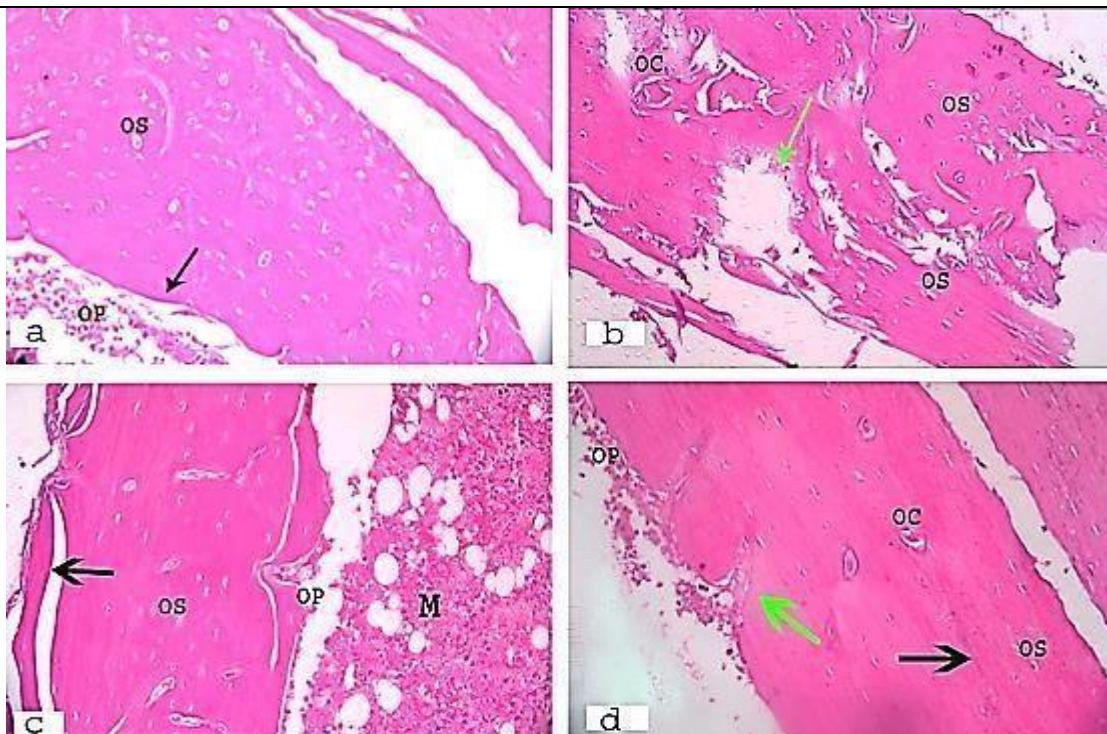
similar to control group. Section of compact bone femur diaphysis of this group showed osteocytes within their lacunae; osteoblasts on the surface facing bone marrow cavity and distinct bone deposition line were also observed (Figure 1C).

A section of cancellous bone of this group appeared nearly similar to control showing thick bone trabeculae, filled bone marrow cavity and normal bone cortex (Figure 2C).

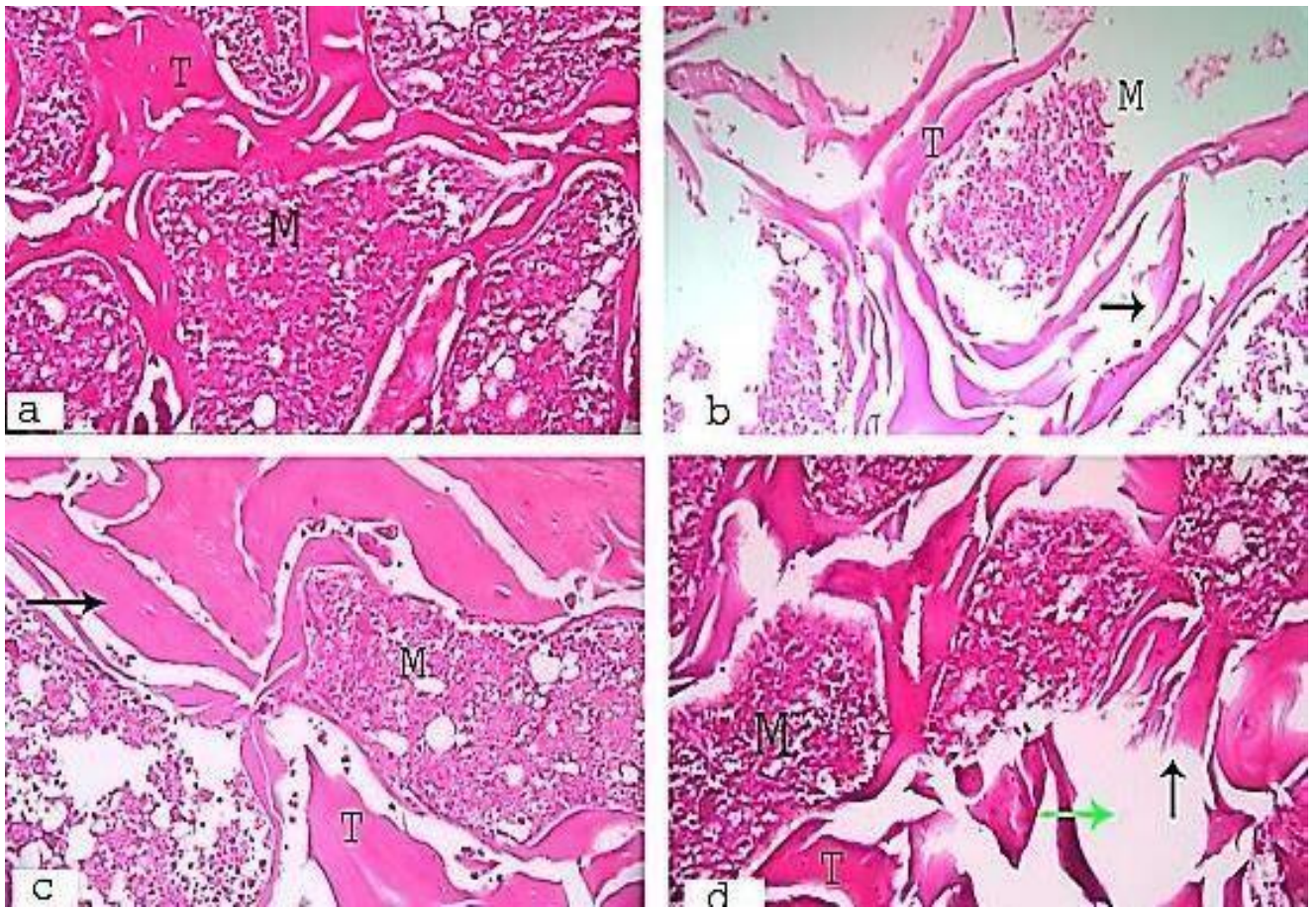
**Group IV (Glucocorticoid+ Royal jelly treated group)**

Histology of group IV appeared nearly similar to the control group. Sections of femur compact bone from group IV showed regular bone lamellae with distinct cement line, deep eosinophilic homogenous bone matrix but with few areas of bone resorption , osteocytes inside their lacunae , multinucleated osteoclasts and multiple osteoblasts lining smooth endosteum (Figure 1d).

A section of cancellous bone of this group appeared nearly similar to control but there some wide empty marrow cavities and few erosions (Figure 2d).



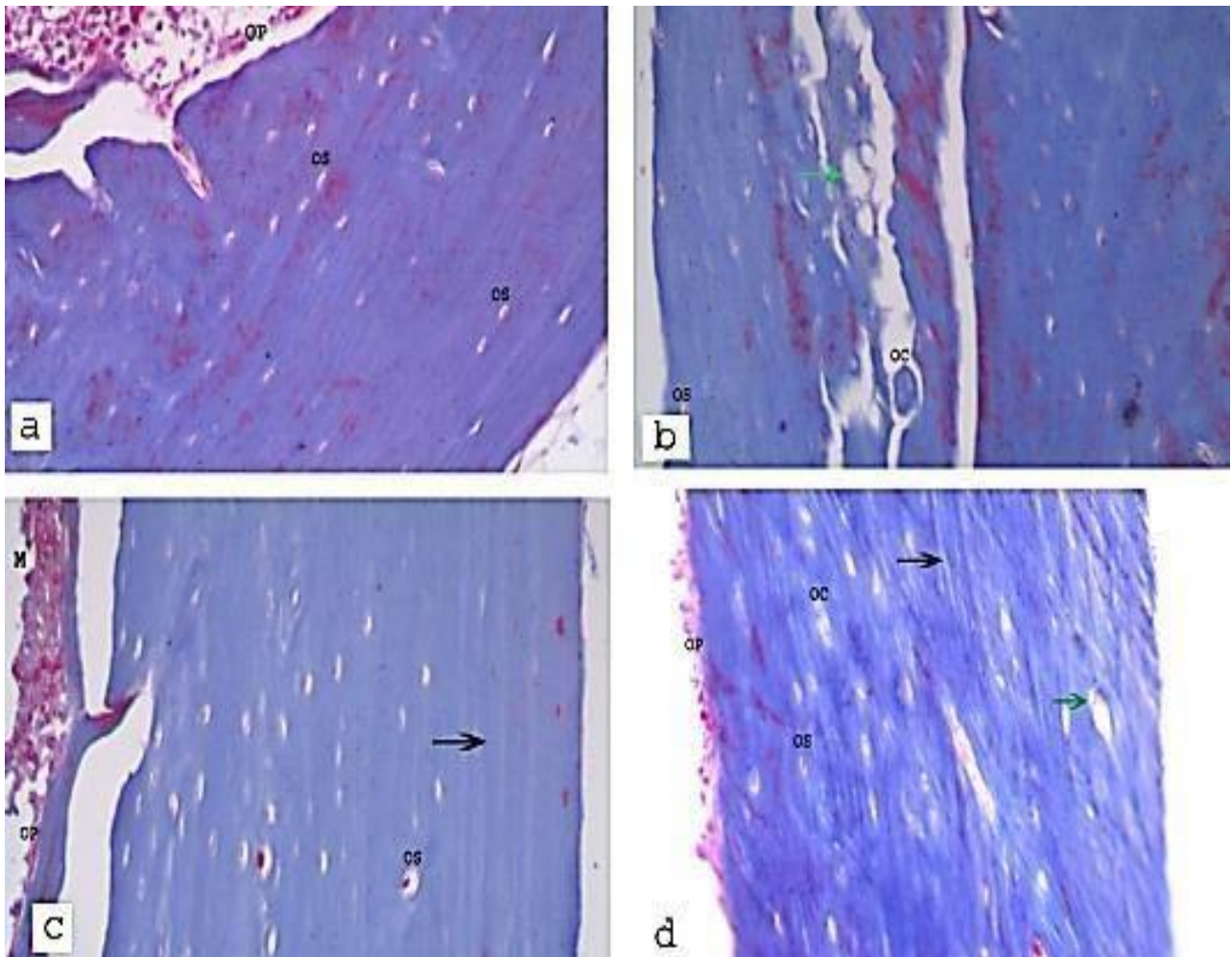
**Figure (1):** (a) Photomicrograph of a section of compact bone femur diaphysis of control group showing osteocytes within their lacunae (OS), osteoblasts (OP) on the surface facing bone marrow cavity and bone deposition lines (black arrow). (b) Glucocorticoid treated group showing bone resorption areas (green arrow), osteoclasts (OC) located in area of bone resorption , some osteocytes in their lacunae with pyknotic nuclei (OS).(C) Photomicrograph of a section of femur diaphysis compact bone of Glucocorticoid + alpha lipoic acid treated group showing osteocytes within their lacunae (OS), osteoblasts (OP) on the surface facing bone marrow cavity (M) and bone deposition lines (black arrow). (d) Photomicrograph of a section of compact bone femur diaphysis of Glucocorticoid+ Royal jelly cured group showing osteoclasts (OC), few areas of bone resorption (green arrow), osteocytes within their lacunae (OS), osteoblasts (OP) on the surface facing bone marrow cavity and bone deposition lines (black arrow). (H&E X 200)



**Figure (2):** (a) Photomicrograph of a section of cancellous bone of adult control male rat showing normal organization of bone trabeculae (T) with normal marrow cavities (M). (b) Photomicrograph of a section of cancellous bone of Glucocorticoid treated group showing broadly spaced thin bone trabeculae (T), regions of trabecular destruction (black arrow) and wide marrow spaces (M). (c) Photomicrograph of a section of cancellous bone of Glucocorticoid + alpha lipoic acid treated group showing thick bone trabeculae (T), filled bone marrow cavity (M) and normal bone cortex (arrow). (d) Photomicrograph of a section of cancellous bone of Glucocorticoid + royal jelly treated group showing bone trabeculae (T) with few erosions (black arrow) and marrow cavities (M) nearly similar to control but there some wide empty marrow cavities (green arrow). (H&E X200)

**Masson trichrome stain:**

An increased amount of collagen fibers was detected within the cortex of Masson stained bone sections of control group (Figure.3a). Decreased amount of collagen fibers within the cortex was noticed in the Masson stained bone sections of (Glucocorticoid treated group) (Figure.3b). Increased amount of collagen fibers within the cortex was seen in Masson stained bone sections of (Glucocorticoid + alpha lipoic acid treated group) (Figure.3c). Increased amount of collagen fibers was seen within the cortex of Masson stained bone sections of (Glucocorticoid + Royal jelly treated group) (Figure.3d).



**Figure (3):** (a) Photomicrograph of a section of compact bone femur diaphysis of control group viewing bone matrix is regularly arranged and mostly formed of normal bluish collagen fibers, osteocytes within their lacunae (OS) and osteoblasts (OP) are seen. (b) Photomicrograph of a section of compact bone femur diaphysis of Glucocorticoid cured group showing Osteoclasts (OC) located in bone resorption areas (Green arrow), some osteocytes in their lacunae (OS). (C) Photomicrograph of a section of compact bone femur diaphysis of Glucocorticoid + alpha lipoic acid treated group showing osteocytes within their lacunae (OS), Osteoblasts (OP) on the surface facing bone marrow cavity (M) and regular bluish bone lamellae in the form of collagen fibers (black arrow). (d) Photomicrograph of a section of compact bone femur diaphysis of Glucocorticoid + royal jelly cured group showing osteoclasts (OC), empty lacunae (green arrow), few osteocytes within their lacunae (OS), osteoblasts (OP) on the surface facing bone marrow cavity and regular bone lamellae in the form of collagen fibers (black arrow). (Masson's trichrome stain X 200)

**Alizarin red Stain:**

The intensity of red color after Alizarin red staining of bone sections was decreased in glucocorticoid treated group (Figure 4b) in comparison to the control group (Figure 4a). While , the intensity of red color in group III (Glucocorticoid + alpha lipoic acid treated group) and group IV (Glucocorticoid + Royal jelly treated group) in Alizarin red stained bone sections (Figures 4c & 4d) was increased in comparison to group II (Glucocorticoid treated group).

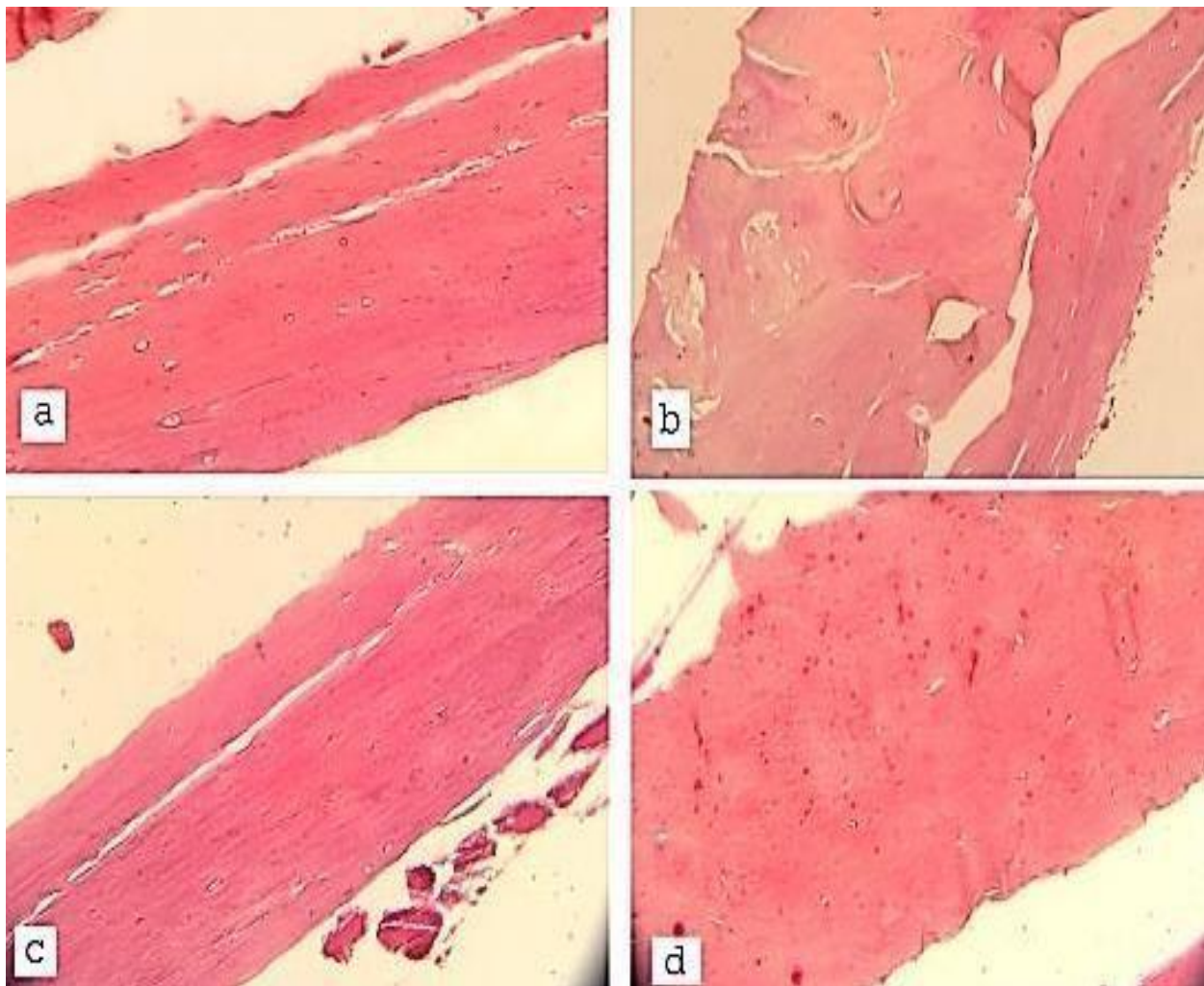


Figure (4): (a) Photomicrograph of a section of compact bone femur diaphysis of control group displaying bone matrix is regularly arranged and showing intense red coloration due to increased mineralization and osteocytes within their lacunae . (b) Photomicrograph of a section of compact bone femur diaphysis of glucocorticoid cured group showing area of bone fracture and bone resorption, note decreased red color due to decreased bone mineralization. (C) Photomicrograph of a section of compact bone femur diaphysis of glucocorticoid + alpha lipoic acid treated group showing osteocytes within their lacunae, increased red colour due to increased bone mineralization. (d) Photomicrograph of a section of compact bone femur diaphysis of glucocorticoid + royal jelly cured group showing empty lacunae, increased red colour due to increased mineralization. (Alizarin red X200)

## Immunohistochemical Observations

### *Osteopontin immunostained sections*

Femur sections of the control rats (group I) exhibited positive OPN immunoreaction that appeared as brown cytoplasmic deposits in osteoblasts lining the endosteum, osteocytes and in the bone matrix (Figure 5a). While sections of group II (Glucocorticoid treated group) displayed negative OPN immunoreactivity within both the osteoblasts, osteocytes and bone matrix (Figure 5b). Sections from group III showed brown positive OPN immunoreaction in the cytoplasm of osteoblasts, osteocytes and in bone matrix (Figure 5c). Also in group IV; there was positive OPN immunoreaction in both osteoblasts, osteocytes and bone matrix (Figure 5d).

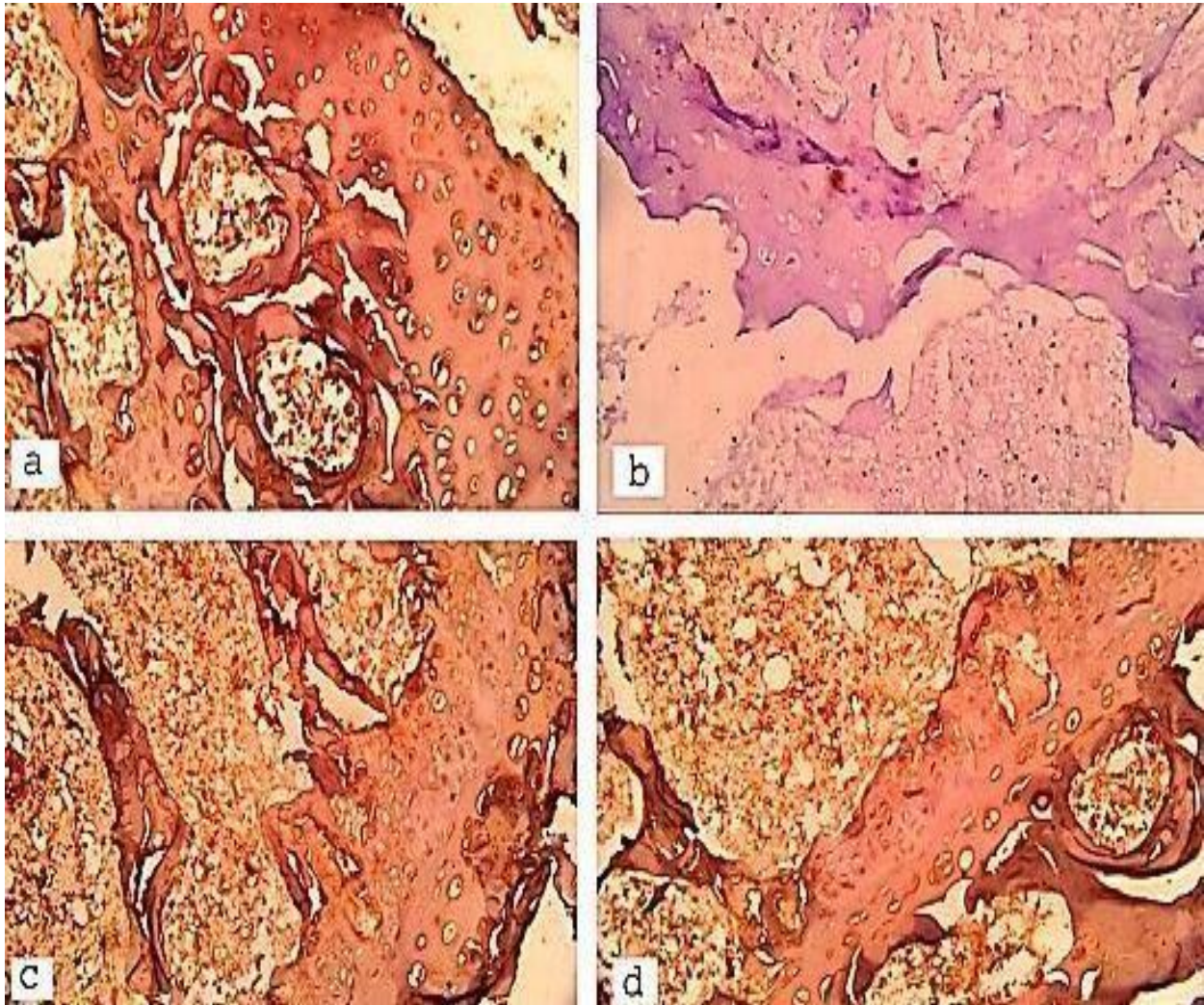


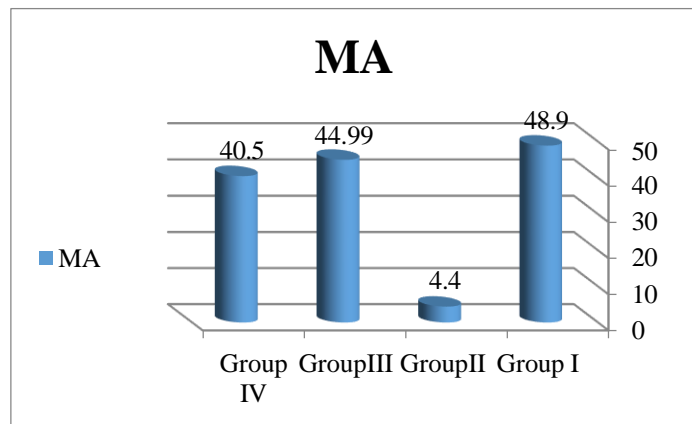
Figure (5) : (a) An immunostained photomicrograph of rat femur diaphysis of the control group showing increased brown coloration that indicates positive cytoplasmic reaction. (b) An Immunostained photomicrograph of rat femur diaphysis of glucocorticoid treated group showing decreased brown coloration that indicates a negative cytoplasmic reaction. (C) An immunostained photomicrograph of rat femur diaphysis of glucocorticoid + alpha lipoic acid treated group showing increased brown coloration that indicates positive cytoplasmic reaction. (d) An immunostained photomicrograph of rat femur diaphysis of glucocorticoid + royal jelly treated group showing increased brown coloration that indicates positive cytoplasmic reaction. (Osteopontin immune staining with counter stain hematoxylin X 200)

**Morphometric results:**

The area percent of osteopontin immunoreactivity for all groups was represented in Table 1 and histogram 1. The area percent of osteopontin immunoreactivity highly significantly decreased in group II in comparison to the control group ( $P < 0.02$ ). Area percent of osteopontin immunoreactivity in group III decreased without a significant difference when compared to the control group ( $P > 0.05$ ) but it had a high significant increase in comparing with group II ( $P < 0.02$ ) and it had an insignificant increase in comparison with group IV ( $P > 0.05$ ). Also, in group IV the area percent of osteopontin immunoreactivity markedly improved with an insignificant difference as compared to the control group ( $P > 0.05$ ) and it had high significant increase in comparing with group II ( $P < 0.02$ ).

**Table (1): Shows mean values of area percent immunoreactivity of osteopontin ± SD in the four groups**

Mean % ± SD	Group I	Group II	Group III	Group IV
MA Osteopontin	48.9 ± 9.1	4.4 ± 4.7	44.99 ± 8	40.5 ± 10.8
Significance ≤ 0.05	With group II	With groups I,III & IV	With group II	With group II

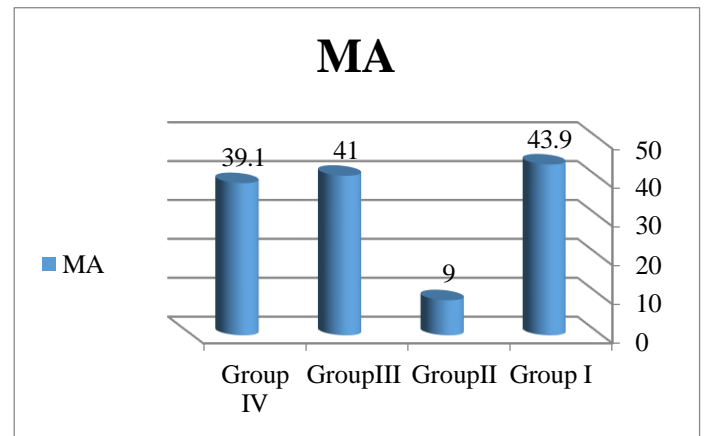


**Histogram (1): Shows mean values of area percent osteopontin immunoreactivity in the four groups.**

The area % of collagen fiber deposition for every group was represented in Table 2 and histogram 2. There was a significant reduction in the area% of collagen fiber deposition ( $P \leq 0.02$ ) in group II comparing with groups I,III & IV. But area percentage of collagen deposition decreased in groups III & IV with insignificant difference comparing with the control group ( $P > 0.05$ ). Also, the area % of collagen deposition reduced insignificantly in group IV comparing with group III ( $P > 0.05$ ).

**Table (2): Shows mean values of area percent of collagen deposition ± SD in the four groups**

Mean % ± SD	Group I	Group II	Group III	Group IV
Masson%	43.9 ± 3.6	9 ± 2.6	41 ± 1.58	39.1 ± 0.75
Significance ≤ 0.05	With group II	With groups I,III & IV	With group II	With group II



**Histogram (2): Shows mean values of area percent of collagen deposition in the four groups.**

**DISCUSSION**

Osteoporosis is a general skeletal disturbance described by decreased bone mass and microstructural impairment of bone matter, with a resulting defective bone strength and increased tendency of breakage<sup>(20)</sup>. In the present investigation, we used male albino rats in the induction of osteoporosis, to avoid hormonal changes in female rats like estrogen deficiency that may cause osteoporosis. We investigated the diaphysis of the femur with its compact and trabecular bone, we used it because the rat and human femurs are similar at the macrostructural and microstructural level<sup>(21)</sup>. The method by which glucocorticoids make bone damage is incompletely understood and complex<sup>(22)</sup>. Enhancement of bone resorption, and decreased bone formation, are the major effects of the steroid<sup>(23)</sup>. It also directly affects the differential activity and life period of osteocytes & osteoblasts. Genes important for bone formation as transforming growth factor-β, fibronectin, insulin-like growth factor-1 and genes responsible for the formation of collagen A1, are inhibited mainly by glucocorticoid<sup>(24)</sup>. In addition, glucocorticoid may accelerate the formation of receptor activators of nuclear factor-κ B ligand (RANKL) and decrease the production of osteoprotegerin, leading to propagation of osteoclast activity and persistence<sup>(25)</sup>.



In our study, microscopic examination of haematoxylin & eosin stained sections of the glucocorticoid treated group showed multiple erosion cavities in the cortex of compact bone and trabeculae of cancellous bone. There were areas of pale stained matrix, indistinct cement lines, decreased bone thickness, thinning and interruption of bone trabeculae, and empty osteocytes lacunae. These findings go in agreement with the former studies <sup>(12, 26 & 27)</sup> which mentioned that osteoporosis in cancellous bone might be expressed as erosion of trabeculae. Wide bone marrow spaces appeared between trabeculae containing fewer hemopoietin cells and abundant adipocytes than the control group with eroded and irregular endosteum. Low expression of OPN as a bone mineralization marker was formerly reported and evident histologically and by morphometric study. This finding was established by the significant decrease in OPN expression in glucocorticoid treated group in comparison with the control one, OPN expression reflects the activity of osteoblasts, their maturation and the beginning of bone mineralization activity <sup>(28 & 19)</sup>.

Demineralization of bone following corticosteroid was evident in Masson's trichrome and alizarin red stained sections where the bone was formed mostly of the immature matrix with small areas of mineralization that might be attributed to the decreased number of osteoblasts responsible for bone mineralization. This was confirmed histologically and by statistical analysis, where there is a noticeable decrease in the average area percent of collagen fibers when compared with the control, which agreed with **Mityas et al.** and **Al-Bogami et al.** <sup>(21 & 29)</sup>.

In this study, signs of new bone formation and normal histological structures of osteoid tissue were observed in haematoxylin & eosin stained femur slices of rats received corticosteroid with alpha-lipoic acid, including new matrix formations and continuous cement line, decrease bone resorption, normal osteocytes and increase the thickness of bone trabeculae of cancellous bone, these finding reported also by **Radzki et al.** <sup>(11)</sup>. Bone resorption is reduced in ALA-treatment by inhibition of osteoclast formation as clarified by **Lu et al.** <sup>(9)</sup>, where it directly suppresses activation of nuclear factor kappa B ligand (RANKL) that enhances osteoclast synthesis intermediated signals performing as thiol antioxidant. Similarly, <sup>(10)</sup> recognized that ALA was combined with decrease in oxidative tension, as prevention of inflammatory cytokine stimulation and nuclear factor-kappa B DNA binding action. Additionally, lipoic acid decreases bone damage in vivo and osteoclast creation in vitro. Mutually, the usage of lipoic acid as a combined therapy for rheumatoid arthritis might be a new useful combination. **Rochette et al.** <sup>(30)</sup> went in line with this who indicated that, oxidative activity is a significant moderator for bone damage. TNF- $\alpha$ , has a serious role in bone resorption, it increased intracellular oxidative

activity. These researchers also proposed that, ALA could have possible beneficial applications in the prevention or diminishing bone damage associated with high oxidative stress by TNF $\alpha$ . Also in our work , Increased amount of collagen fibers within the cortex was seen in Masson stained bone sections of group III and the intensity of red color in Alizarin red-stained bone sections was increased in comparison to group II. In the present study, examination of H & E stained femur sections from group IV showed preservation in bone microstructure similar to the control; regular bone lamellae with distinct cement line, deep eosinophilic homogenous bone matrix, osteocytes inside their lacunae and multiple osteoblasts lining smooth endosteum were noticed but with few areas of bone resorption. These findings are in agreement with **Kafadar et al.** <sup>(8)</sup> who said that RJ may have a useful effect on organic changes of osteoporotic bone tissue. RJ group conserved the organization of trabeculae as same as the control group. Royal Jelly may be beneficial in treatment of osteoporosis in males, that may be caused by a reduction of androgen as it contains testosterone . Referring to all of these properties, RJ may be very effective in the management of osteoporosis.

Also in this work, Increased amount of collagen fibers within the cortex was seen in Masson stained bone sections of group IV and the intensity of red color in Alizarin red stained bone sections was increased in comparison to group II. This goes in line with **Sadegh et al.** <sup>(7)</sup> Who proved that Royal jelly shows estrogen-like characters and activates chondriogenesis.

## CONCLUSION

Chronic use of glucocorticoid in adult male albino rats caused osteoporosis that could be reversed by administration of alpha lipoic acid and royal Jelly.

**Conflict of interest:** The authors declare no conflict of interest.

**Sources of funding:** This research did not receive any specific grant from funding agencies in the public, commercial, or not-for-profit sectors.

## REFERENCES

1. **Guo Y, Liu Y, Shi C et al. (2021):** Remote-controllable bone-targeted delivery of estradiol for the treatment of ovariectomy-induced osteoporosis in rats. *J Nanobiotechnol.*, 248 : 1-18.
2. **SUN X, Fengbo L, Xinlong M et al. (2015):** The effects of combined treatment with Naringin and Treadmill exercise on osteoporosis in ovariectomized rats. *Sci Rep.*, 5: 1-8.
3. **Ge X, Zhou G (2021):** Protective effects of naringin on glucocorticoid-induced osteoporosis through regulating the PI3K /Akt/mTOR signaling pathway. *Am J Transl Res.*, 13(6): 6330–6341.

4. **Yousefzadeh N, Kashfi K, Jeddi S et al. (2020):** Ovariectomized rat model of osteoporosis: a practical guide. *Excli J.*, 19: 89–107.
5. **Zhao J, Li Y, Zhang H et al. (2019):** Preventative effects of metformin on glucocorticoid-induced osteoporosis in rats. *Journal of Bone and Mineral Metabolism*, 37: 805–814.
6. **Hermínia L, Sousa T, Valeriano E et al. (2017):** Effects of glucocorticoid-induced osteoporosis on bone tissue of rats with experimental periodontitis. *Archives of Oral Biology*, 77: 55-61.
7. **Sadegh A, Torkestani H, Sharifi S et al. (2020):** Effects of concurrent use of royal jelly with hydroxyapatite on bone healing in rabbit model radiological and histopathological evaluation. *Heliyon*, 6:1-5.
8. **Kafadar I, Güney A, Türk C et al. (2012):** Royal jelly and bee pollen decrease bone loss due to osteoporosis in an oophorectomized rat model. *Joint diseases & related surgery. Eklem Hastalik Cerrahisi.*, 23(2):100-105.
9. **Lu S, Wang C, Jin Y et al. (2017):** The osteogenesis-promoting effects of alpha-lipoic acid against glucocorticoid-induced osteoporosis through the NOX4, NF-kappaB, JNK and PI3K/AKT pathways. *Sci Rep.*, 7(1): 1-16.
10. **Roberts J, Moreau R (2015):** Emerging role of alpha-lipoic acid in the prevention and treatment of bone loss. *Nutrition Reviews*, 73(2): 116–125.
11. **Radzki R, Bienko M, Pogoda A et al. (2022):** Lipoic acid (LA) dose-dependently protects bone losses in the mandible of rats during the development of osteopenia by inhibiting oxidative stress and promoting bone formation. *Biomedicine & Pharmacotherapy*, 146: 1-8.
12. **Pizzino G, Galfo F, Oteri G et al. (2017):** Adenosine Receptor Stimulation Improves Glucocorticoid-Induced Osteoporosis in a Rat Model. *Front Pharmacol.*, 8(558):1-11.
13. **Aslan A, Can M, Gok O et al. (2022):** The inducing of caspase and Bcl-2 pathway with royal jelly decreases the muscle tissue damage exposed with fluoride in rats. *Environ Sci Pollut Res.*, 29: 10547–10557.
14. **Leary S, Underwood W, Anthony R et al. (2020):** AVMA Guidelines for the Euthanasia of Animals: 2020 Edition., Pp. 82–91. <https://icwdm.org/wp-content/uploads/2021/03/2020avma-euthanasia-guidelines.pdf>
15. **Suvarna S, Layton C, Bancroft J (2019):** Bancroft's Theory and Practice of Histological Techniques. 8<sup>th</sup> edition. Churchill Livingstone, China. Pp. 280-304. <https://www.us.elsevierhealth.com/bancrofts-theory-and-practice-of-histological-techniques-9780702068645.html>
16. **Alwahaibi N, Al-Himali S, Kumar J (2012):** Capability of Hematoxylin and Eosin Stain to Demonstrate Hemosiderin in Bone Marrow Trepchine Biopsy. *J Cytol Histol.*, 3 (3):1-3.
17. **Zidan R, Elnegrís H (2015):** Effect of homocysteine on the histological structure of femur in young male albino rats and the possible protective role of folic acid. *Journal of Histology & Histopathology*, 2 (16): 1-12.
18. **Rafiei H, Ahmadi Z, Ashrafizadeh M (2018):** Effects of Orally Administered Lead acetate II on Rat Femur Histology, Mineralization Properties and Expression of Osteocalcin Gene. *Int Biol Biomed J.*, 4(3): 149-155.
19. **Ali A (2020):** Histological and Immunohistochemical Study on the Effect of Valporic Acid on the Femur of Adult Male Guinea Pigs and the Possible Protective Role of L-carnitine. *Egyptian Journal of Histology*, 43(3): 718-731.
20. **Kasem M, Khedr E, Abdel-Aleem A et al. (2016):** Histological Effect of Bisphosphonate, Vitamin D and Olive Oil on Glucocorticoid Induced Osteoporosis (Gio) in Albino Rat. *The Egyptian Journal of Hospital Medicine*, 65: 699- 708.
21. **Mityas G, Tawfik S, El-bakery N et al. (2019):** Histological Study of the Possible Protective Effect of Lycopene on Glucocorticoid-Induced Osteoporosis in Adult Male Albino Rat. *Med J Cairo Univ.*, 87(3): 2121-2134.
22. **Ersek A, Santo E, Vattakuzhi Y et al. (2016):** Strain dependent differences in glucocorticoid-induced bone loss between C57BL/6J and CD-1 mice. *Sci Rep.*, 6: 1-10.
23. **Jia D, O'Brien A, Stewart S et al. (2006):** Glucocorticoids act directly on osteoclasts to increase their life span and reduce bone density. *Endocrinology*, 147(12): 5592– 5599.
24. **Sambrook P (2007):** Anabolic therapy in glucocorticoid-induced osteoporosis. *N Engl J Med.*, 357: 2084-2086.
25. **Tsugeno H, Fujita T, Goto B et al. (2002):** Vertebral fracture and cortical bone changes in corticosteroid-induced osteoporosis. *Osteoporosis International*, 13: 650-656.
26. **Liu Y, Cui Y, Chen Y et al. (2015):** Effects of dexamethasone, celecoxib, and methotrexate on the histology and metabolism of bone tissue in healthy Sprague Dawley rats. *Clinical Interventions in Aging*, 10:1245-1253.
27. **Kobza A, Herman D, Papaioannou A et al. (2021):** Understanding and Managing Corticosteroid-Induced Osteoporosis. *Open Access Rheumatology: Research and Reviews*, 13: 177-190.
28. **Elkalawy S, Abo Gazia M, Elekhtiar S et al. (2020):** Collagen Hydrolysate Against Fluvoxamine Maleate Induced Osteoporosis in Albino Rats: A Histological and Immunohistochemical Study. *Egyptian Journal of Histology*, 43(4): 988-1007.
29. **Al-Bogami M, Jawad A, Magged R (2015):** Bone loss in osteoporosis and arthritis: Pathogenesis and therapeutic strategies. *Saudi Med J.*, 35(3):224-233.
30. **Rochette L, Ghibu S, Richard C et al. (2013):** Direct and indirect antioxidant properties of  $\alpha$ -lipoic acid and therapeutic potential. *Mol Nutr Food Res.*, 57(1):114-125.